

Cephalometric oropharynx and oral cavity analysis in Chiari Type I: A retrospective case-control study

Aintzane Urbizu, Alex Ferré, Maria-Antonia Poca, Alex Rovira, Juan Sahuquillo, Bryn A. Martin, Alfons Macaya

Purpose

Chiari patients often report symptoms related to pharyngeal dysfunction such as choking, regurgitation, dysphagia, aspiration, chronic cough, and sleep disorders. In addition, tracheal intubation is often difficult in these patients. The purpose of this study was to analyze the morphological features of the oropharynx and oral cavity in patients with Chiari malformation Type I to help identify underlying anatomical anomalies leading to these debilitating symptoms.

Methods

Seventy-six adult patients with symptomatic Chiari malformation Type I with cerebellar tonsillar descent greater than 5 mm and a small posterior cranial fossa and 49 sex-matched controls were selected to perform a retrospective case-control MRI-based morphometric study in a tertiary hospital. Eleven parameters of the oropharyngeal cavity on midsagittal T1-weighted MRI were measured and the average values between patients and control cohorts were compared. Correlations between significant oropharyngeal measurements and posterior fossa measurements were calculated.

Results

Significant differences were detected for several oropharynx and oral cavity measures in the patient cohort, primarily involving the length and thickness of the soft palate ($p = 9.5E-05$ and $p = 3.0E-03$, respectively). A statistically significant ($p < 0.01$) moderate correlation between some of these variables and posterior cranial fossa parameters was observed.

Conclusions

Adult patients with classic CMI were found to have several differences in the oropharynx and oral cavity morphology compared with a sex-matched control population. The most significant of these morphological differences was that patients with CMI had a longer and thinner soft palate; this factor may explain in part the respiratory complications, dysphagia, and swallowing problems that are often encountered in CMI. Prospective studies focused on objective pharyngeal functional measures will determine whether a correlation can be established between the altered structures we have identified and specific oropharyngeal symptomatology.

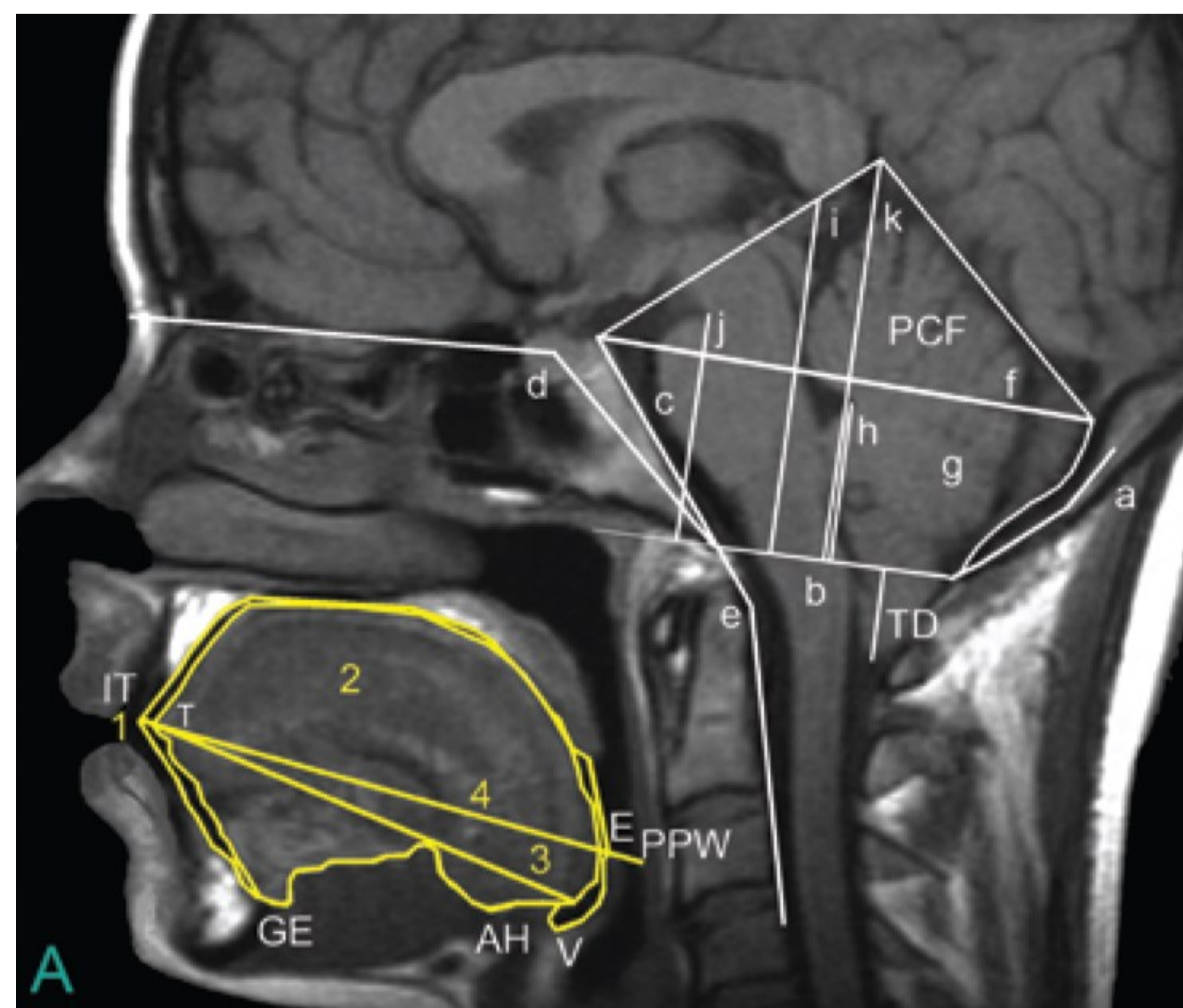


TABLE 2. Cephalometric oropharynx analysis in patients and control subjects

Variable	Patients (n = 76)*	Controls (n = 49)*	p Value†
Age (yrs)	42.1 ± 12.2	35.2 ± 6.8	—
Sex (M/F)	29:47	19:30	—
Tonsillar descent (mm)	11.0 ± 4.5	-5.0 ± 3.7	—
Oral cavity area (cm ²)	29.1 ± 4.0	30.7 ± 3.8	0.03
Tongue area (cm ²)	26.8 ± 3.7	27.9 ± 3.2	0.09
Tongue length (mm)	70.7 ± 6.5	69.6 ± 5.5	0.34
Anterior-posterior pharyngeal cavity diameter (mm)	82.7 ± 6.3	83.0 ± 6.3	0.76
Vertical airway length (mm)	63.1 ± 7.8	62.1 ± 6.9	0.48
Length of soft palate (mm)	36.0 ± 4.8	32.6 ± 4.3	9.5E-05
Thickness of soft palate (mm)	10.3 ± 2.1	11.4 ± 1.7	3.0E-03
Narrowest upper pharyngeal airway diameter (mm)	7.7 ± 2.7	7.7 ± 2.3	0.77
Narrowest middle pharyngeal airway diameter (mm)	8.7 ± 2.9	9.4 ± 3.1	0.90
Narrowest lower pharyngeal airway diameter (mm)	4.6 ± 1.9	4.8 ± 2.3	0.23
Distance from tip of epiglottis to odontoid base (mm)	9.6 ± 9.4	6.3 ± 7.5	0.02

— = not applicable.

* Average values (mean ± SD) are indicated for the 11 measurements.

† Statistical significance was modified to $p < 0.0045$ after applying the Bonferroni correction for multiple comparisons.